



Patient Demographics: Female, 21 years old

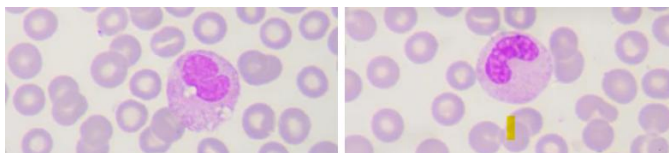
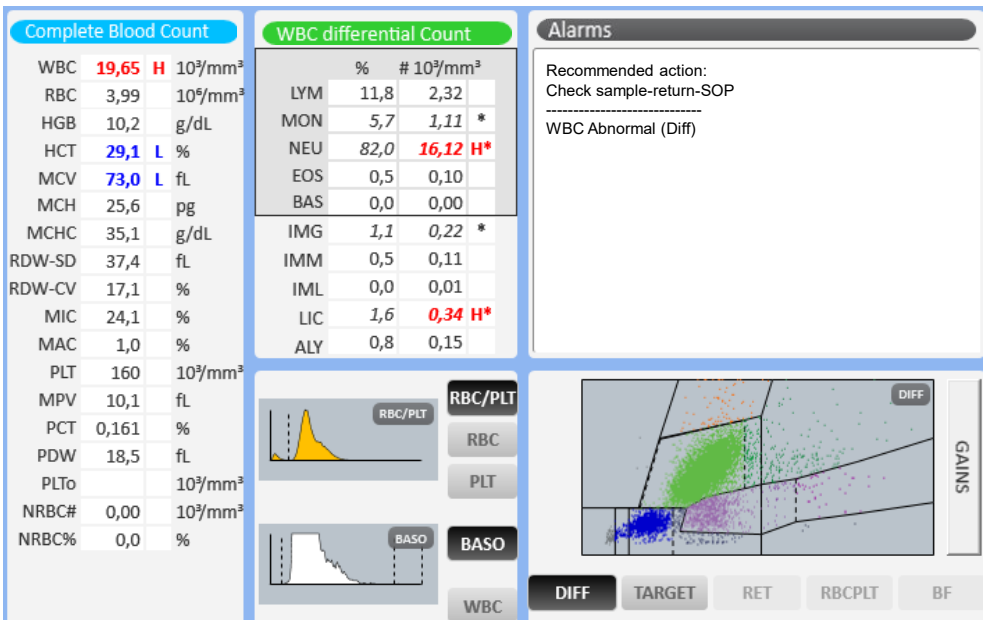
Diagnosis: Sepsis in hepatocellular injury

Other Information: Weakness, pallor, low-grade fever, and mild abdominal pain.

Microscopic Review: Bands: 7%, Neutrophils 75%, Lymphocytes 11.8%, Monocytes 5.7%, Red blood cells with mild hypochromia, mild microcytosis, and occasional elliptocytes.

Other Tests: GGT 70, Creatinine 4.6, Na 134, Mg 1.3, ALT 72

How Yumizen H1500 assisted: Automated detection of immature and activated cells (IMG, IMM, LIC, ALY) → essential for suspicion of infection or marrow activation. Advanced morphological analysis (RDW, MCV, MCH) guides anemia diagnosis and classification. Scatter plots and histograms → allow clear visualization of hematologic deviations.



Subscribe to Chase the Case: <https://horiba.link/chase-case>

Contact: webmaster.med@horiba.com

Editorial Team: Daniele Pacheco,

Dr. Prakash Suvasia, Sebastien Raimbault - HORIBA Brazil & France

This clinical case has been provided by a laboratory in Brazil