



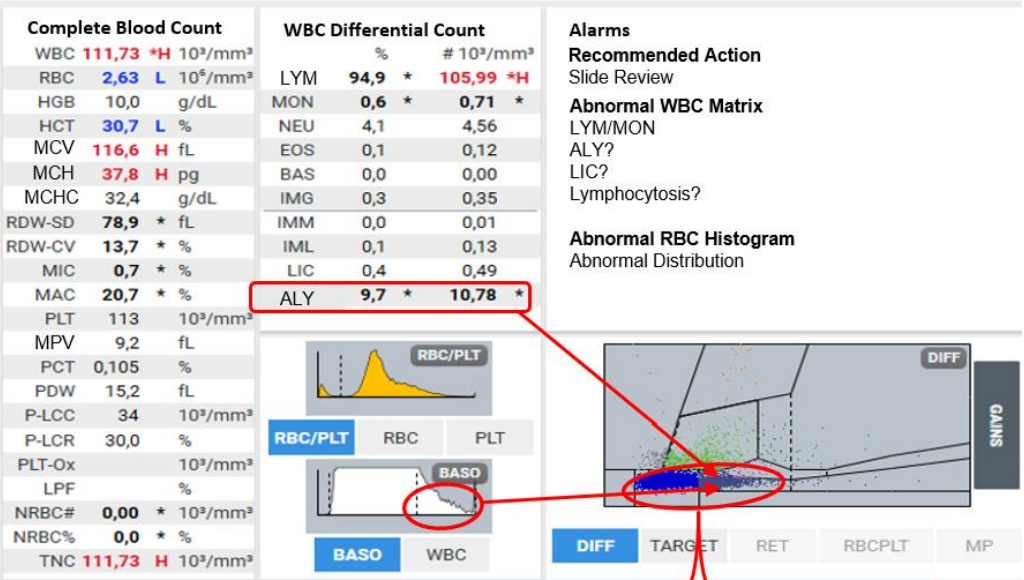
**Patient Demography:** Male, 65 years old

**Symptoms:** Generalized weakness, loss of appetite, low grade fever, weight loss

**Diagnosis:** Lymphoproliferative disorder

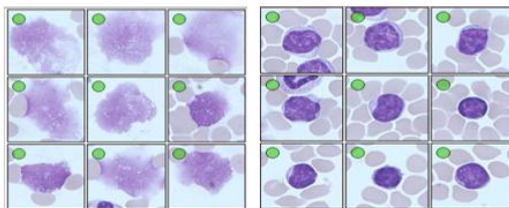
**Microscopic Review:** Prolymphocytes: 5%, neutrophils: 6%, lymphocytes: 85%, monocytes: 3%, eosinophils: 1%. Presence of small to few atypical lymphocytes; Lymphocytes with standard chromatin; Presence of cellular shadows from Gumprecht spots / Smudge cells.

**How Yumizen Can Assist:** On the DIFF scattergram, we observe the presence of atypical lymphocytes and immature lymphocytic cells from the Chronic Lymphocytic Leukemia (CLL). On the Baso histogram, we observe large cells on the right of the curve which correspond to the abnormal forms cells of the CLL.



Smudge Cells

Atypical Lymphocytes



Subscribe to Chase the Case: <https://horiba.link/chase-case>

Contact: [webmaster.med@horiba.com](mailto:webmaster.med@horiba.com)

Editorial Team: Daniele Pacheco, Andreia Rodrigues

Dr. Prakash Suvasia, Sebastien Raimbault - HORIBA Brazil & France

This clinical case has been provided by a laboratory in Brazil.