



Patient Demography: Female aged 17 years, outpatient at a physician's clinic

Symptoms: Fever with chills

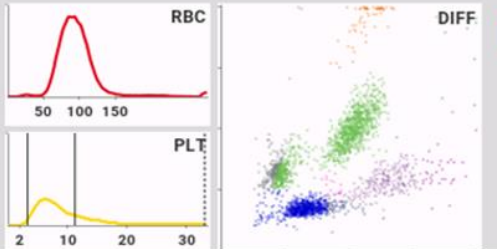
Diagnosis: Malaria

Microscopy: Ring forms of Plasmodium Malaria seen

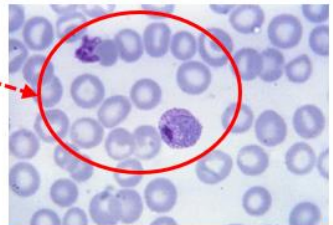
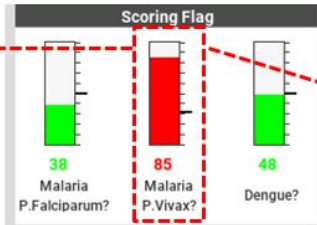
Other Tests: Malaria (Rapid Card Test): Plasmodium Vivax Positive.

How Yumizen Can Assist: This case shows the utility of Malaria Flag on **Yumizen H500** hematology analyzers at a private pathology laboratory for a patient with fever under investigation, during the rainy season when there are many mixed infections like Malaria or Dengue causing fever as a common symptom.

		% 10 ³ /mm ³		% 10 ³ /mm ³		Recommended Actions	
WBC	3.20 * \downarrow 10 ³ /mm ³	NEU	51.1 *	IMG	0.4 *	0.01 *	Slide Review
RBC	4.04 \downarrow 10 ⁶ /mm ³	LYM	33.7 *	IMM	0.1 *	0.00 *	Alarms
HGB	13.3 g/dL	MON	11.5 * h	IML	0.0 *	0.00 *	LMNE
HCT	39.6 \downarrow %	EOS	2.8 *	ALY	3.1 * H	0.10 *	Abnormal differentiation
MCV	97.9 fL	BAS	0.9 *	LIC	1.9 *	0.06 *	Background noise
MCH	32.8 h pg						Synthesis WBC
MCHC	33.5 g/dL						ALY?
RDW-CV	16.3 h %						Suspected Pathologies
RDW-SD	52.8 h fL						Atypical Lymphocytes
MIC	0.9 %						Malaria P. vivax?
MAC	9.2 %						
PLT	121 \downarrow 10 ³ /mm ³						
MPV	8.9 fL						
PCT	0.108 \downarrow %						
PDW	10.2 \downarrow fL						
P-LCC	33 \downarrow 10 ³ /mm ³						
P-LCR	27.4 %						



Malaria Rapid Card Test Positive for Plasmodium Vivax



Microscopy showing Trophozoite forms of Plasmodium Vivax