



**Patient Demography:** Male aged 23 years, outpatient at a physician clinic

**Symptoms:** Fever, body aches

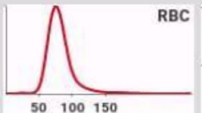
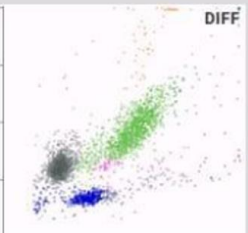
**Diagnosis:** Malaria

**Microscopy:** Ring forms of Plasmodium Malaria seen

**Other Tests:** Malaria (Rapid Card Test): Plasmodium Vivax confirmed by two different kits.

**How Yumizen Can Assist:** This case shows the utility of Infectious Screening Flags on **Yumizen H500** and **Yumizen H550** hematology analyzers at a physician clinic for fever under investigation, even during non-peak time for Malaria infection.

CBC		DIF		Run Date: 20/05/2024 12:46:53 PM	
WBC	5.68 * 10 <sup>3</sup> /mm <sup>3</sup>	%	10 <sup>3</sup> /mm <sup>3</sup>	%	10 <sup>3</sup> /mm <sup>3</sup>
RBC	4.43 10 <sup>6</sup> /mm <sup>3</sup>	NEU	78.4 *h	4.46 *	IMG 1.6 * 0.09 *
HGB	12.7 ‡ g/dL	LYM	15.7 *	0.89 *L	IMM 0.2 * 0.01 *
HCT	37.5 ‡ %	MON	2.7 *‡	0.15 *‡	IML 0.0 * 0.00 *
MCV	84.8 fL	EOS	1.4 *	0.08 *	ALY 2.0 * 0.11 *
MCH	28.7 pg	BAS	1.8 *	0.10 *	LIC 2.1 * 0.12 *
MCHC	33.9 g/dL				
RDW-CV	13.1 %				
RDW-SD	45.3 fL				
MIC	2.8 %				
MAC	4.8 %				
PLT	60 L 10 <sup>3</sup> /mm <sup>3</sup>				
MPV	9.8 fL				
PCT	0.058 ‡ %				
PDW	11.8 fL				
P-LCC	20 ‡ 10 <sup>3</sup> /mm <sup>3</sup>				
P-LCR	33.5 %				

**Recommended Actions**

Slide Review

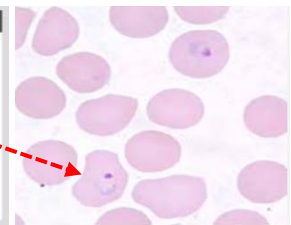
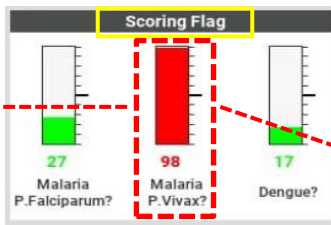
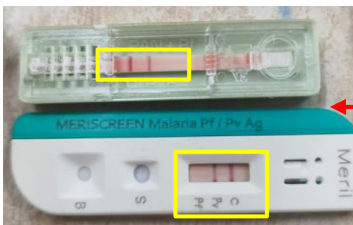
**Alarms**

**LMNE**  
Abnormal differentiation  
Background noise

**Suspected Pathologies**

- Thrombopenia
- Lymphopenia
- Malaria P. vivax?**

NLR : 5.01



**Malaria Rapid Card Test**  
**Positive for Plasmodium Vivax**

**Microscopy shows ring forms**  
**Plasmodium Vivax**

Subscribe to Chase the Case: <https://horiba.link/chase-case>

Contact: [webmaster.med@horiba.com](mailto:webmaster.med@horiba.com)

Editorial Team: Dr. Pushkar Admane, Sandeep Mahajan  
Daniele Pacheco, Andreia Rodrigues, Prakash Suvasia, Sebastien Raimbault  
HORIBA India, Brazil & France

This clinical case has been provided by  
Shreeseva Hospital and Diagnostic  
Centre, Talasari, Maharashtra, India.