



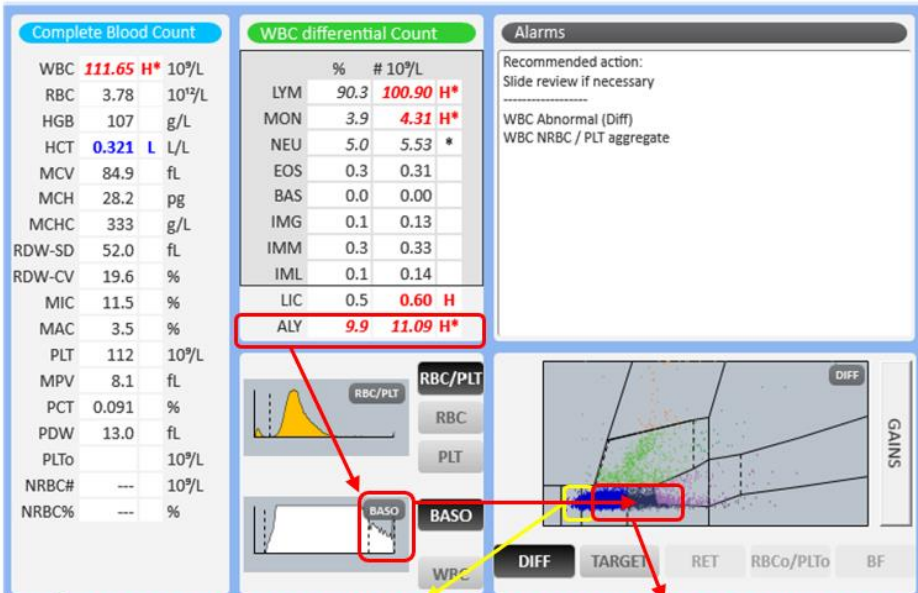
Patient Demography: Male aged 69

Diagnosis: Anemia, Lymphocytosis

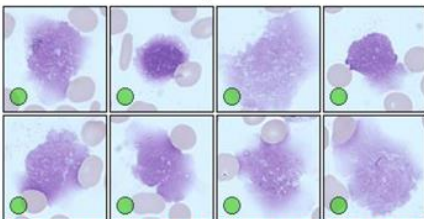
Microscopic Review: Neutrophil: 8%, Lymphocytes (Monomorphic): 73%, Atypical Lymphocytes: 15%, Monocytes: 1%, Eosinophils: 3%. Smudge cells noted.

Other Information: Generalized weakness, weight loss, intermitted cough, fever

How Yumizen can assist: On the DIFF scattergram, we observe the presence of atypical lymphocytes. On the Baso histogram, we observe large cells on the right of the curve which correspond to the abnormal forms of lymphocytes.



Smudge Cells



Monomorphic & Atypical Lymphocytes

