



Patient Demography: Female aged 83

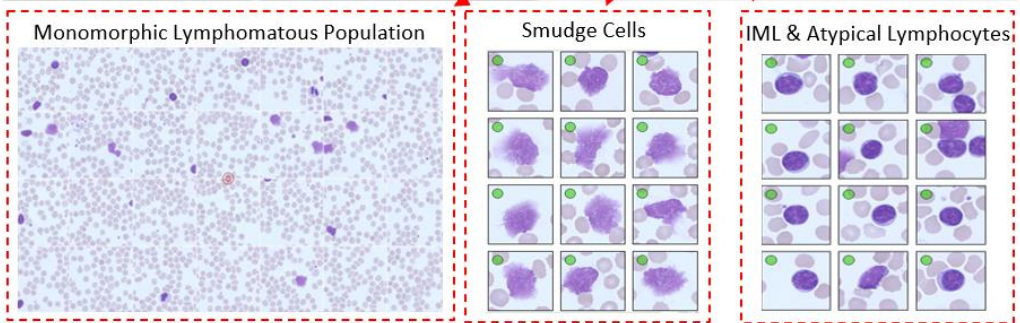
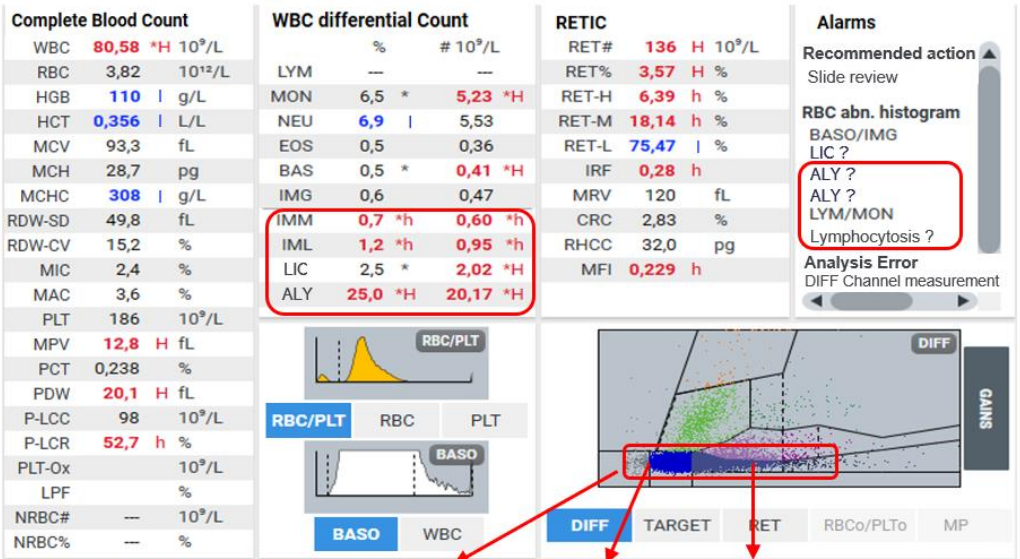
Diagnosis: Lymphoproliferative disorder favors **Chronic Lymphocytic Leukemia**

Microscopic Review: Anisocytosis (+). Lymphomatous population with a high nucleo-cytoplasmic ratio, fine chromatin and sometimes cleaved nucleus, associated with very many smudge cells.

Other Information: Clinical hematology department

How Yumizen Can Assist: The precise and sensitive flagging of Lymphocytosis with ALY and the increase in absolute values of ALY and IML in WBC differential help for a systematic approach in screening Lymphoproliferative Syndrome like CLL.

On the Baso histogram, observe large cells on the right of the curve which correspond to the abnormal form of cells of the CLL.



Subscribe to Chase the Case: <https://horiba.link/chase-case>

Contact: webmaster.med@horiba.com

Editorial Team: Daniele Pacheco, Jaqueline Valente,

Prakash Suvasia, Sebastien Raimbault - HORIBA Medical Brazil, India & France

This clinical case has been provided by a laboratory in France.