

Yumizen

Chase the Case #17

- Acute Promyelocytic Leukemia -



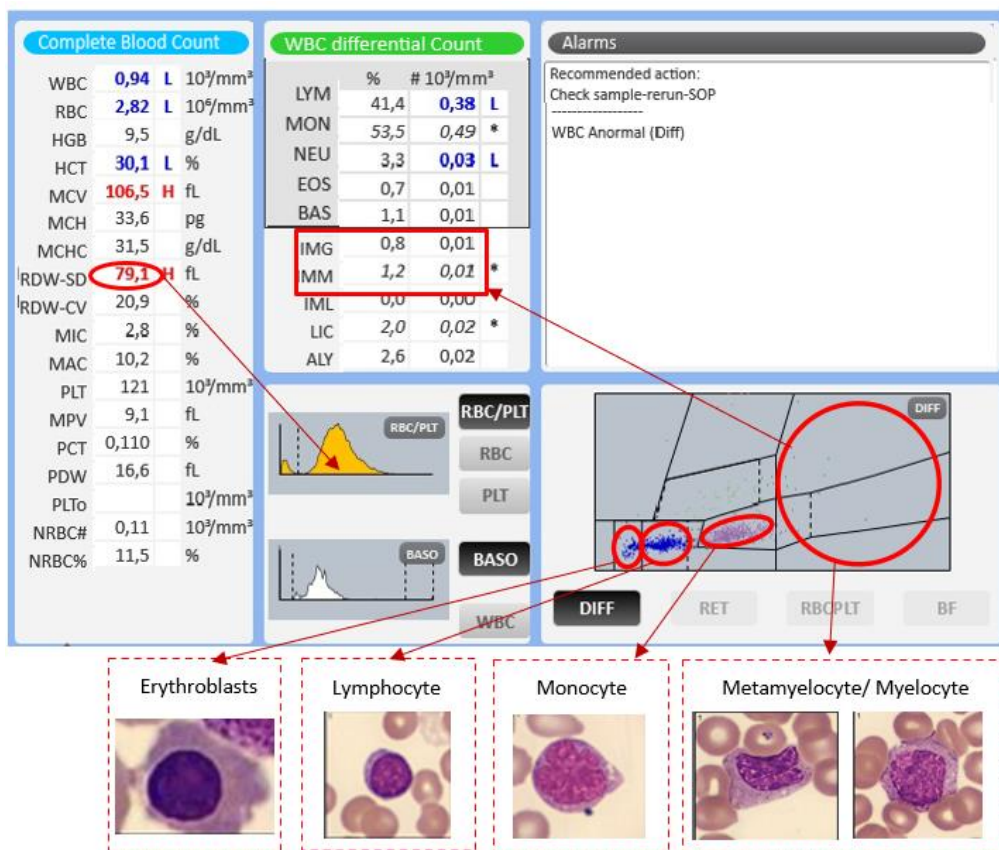
Patient demography: Female aged 55

Diagnosis: Acute Promyelocytic Leukemia

Other information: Amo: scant residual hematopoiesis, massive infiltration by m3 myeloblasts. Immunophenotyping: compatible with acute promyelocytic leukemia, Serology: negative hepatitis (susceptible: negative anti-hbs), HIV: negative

Microscopic review: Myelocyte 1, Metamyelocyte 1, Neutrophils 6, Lymphocytes 45, Monocytes 45, Erythroblasts 9, Atypical lymphocytes 2. Notes: Anisocytosis+, Dacryocytes, Elliptocytes, Macrocytosis, Platelet count in slide= 143,000, Polychromasia

Yumizen assistance: Through the DHSS system, it is possible to perfectly differentiate the entire leukocyte lineage.



Subscribe to Chase the Case: <https://horiba.link/chase-case>

Contact: webmaster.med@horiba.com

Editorial Team:

Daniele Pacheco, Jaqueline Valente, Mariana Bueno

Shubham Rastogi, Sebastien Raimbault - HORIBA Medical Brazil & France

This clinical case has been provided by
a laboratory in Brazil.