

Yumizen

Chase the Case #16



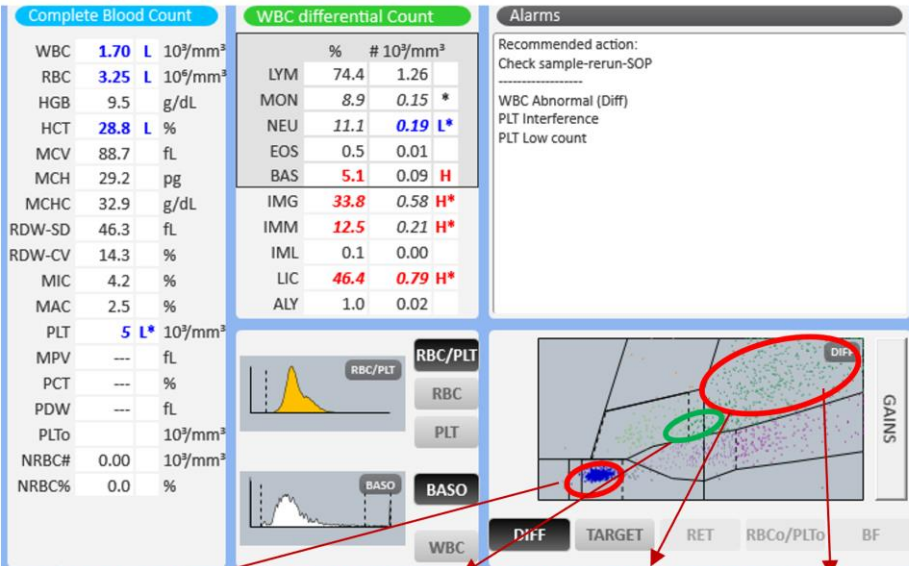
Patient demography: Child, female aged 2

Diagnosis: Chediak-Higashi Syndrome - a rare autosomal recessive disorder that arises from a mutation of a lysosomal trafficking regulator protein, which leads to a decrease in phagocytosis.

Other information: Patient monitoring is being carried out at the hospital – the neutrophil granulations increase according to the intensity of the infection. Medication - interferon, corticosteroids and antibiotics.

Microscopic review: Lymphocytes 72%, myelocyte 7%, metamyelocyte 1%, promyelocyte 1%, monocyte 9%, neutrophils 7%, bands 3%. Presence of large granules in the neutrophil cell line.

Yumizen assistance: The increase in the immature cell count observed in the extended matrix of the Yumizen H2500 helps in the diagnosis of Chediak-Higashi syndrome which has a main morphological characteristic of increased neutrophilic cell granulation. These abnormal neutrophils also generate changes in the LMNE matrix due to the increased light scatter of the granules and relatively high volume of the cells. It appears they may also have a minor impact on the BASO channel.

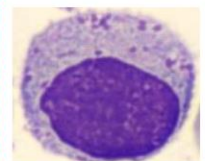
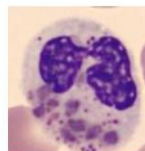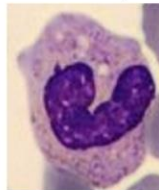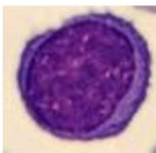


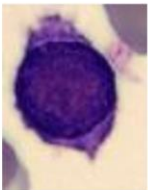Lymphocyte

Band neutrophils

Neutrophils with atypical granules

Myelocyte



Subscribe to Chase the Case: <https://horiba.link/chase-case>

Contact: webmaster.med@horiba.com

Editorial Team:

Daniele Pacheco, Helen Gomes, Jaqueline Valente,

Shubham Rastogi, Sebastien Raimbault - HORIBA Medical Brazil & France

This clinical case has been provided by a laboratory in Brazil.