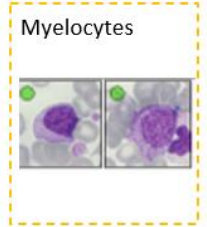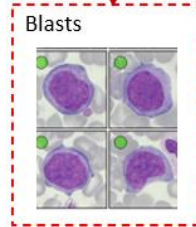
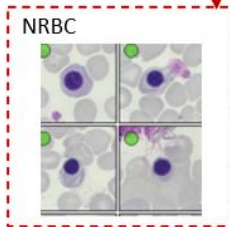

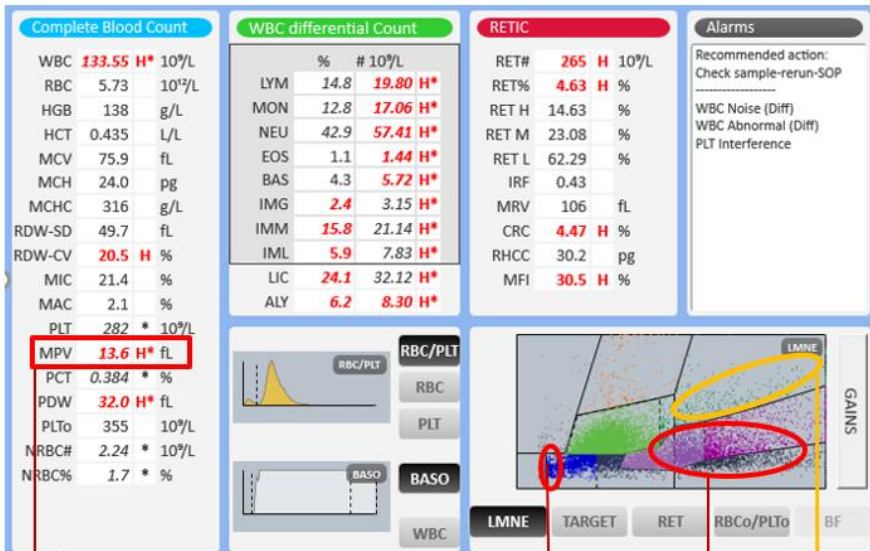


Yumizen

Chase the Case #15



Patient demography: Male aged 78
 Diagnosis: Acute Myeloblastic Leukemia
 Other information: CCU Patient
 Microscopic review: Blast 23%, Myelocyte 1.6%, large platelets



Subscribe to Chase the Case: <https://horiba.link/chase-case>

Contact: webmaster.med@horiba.com

Editorial Team:

Daniele Pacheco, Barbara Lima, Jaqueline Valente,

Shubham Rastogi, Sebastien Raimbault - HORIBA Medical Brazil & France

This clinical case has been provided by
a laboratory in France.