Hematopoiesis

HORIBA Medical

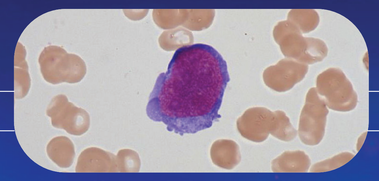

Hemopoietic stem cell
Size :15-25 µm
N/C* ratio : elevated, >0,8
Nucleus : round, oval, fine chromatin, nucleoli or not
Cytoplasm : basophilia, without visible granulation

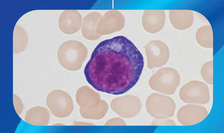

Proerythroblast
Size : 20-30 µm
N/C* ratio : elevated
Nucleus : round nucleus with fine chromatin
Cytoplasm : intensely basophilic

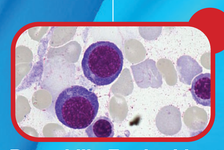

Basophilic Erythroblast
Size : 15 -18 µm
N/C* ratio : elevated
Nucleus : round nucleus, condensed chromatin
Cytoplasm : very basophilic

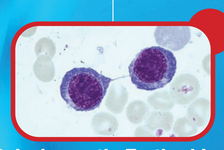

Polychromatic Erythroblast
Size : 10 - 15 µm
N/C* ratio : elevated
Nucleus : round, chromatin is moderately condensed.
Cytoplasm : grayish condensed

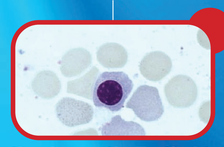

Orthochromatic Erythoblast
Size : 10 µm
N/C* ratio : medium
Nucleus : small round, dense chromatin
Cytoplasm : close color as red blood

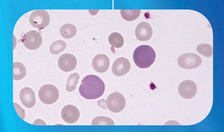

Reticulocyte
Size : > 1 RBC (8-10µm)
Cytoplasm : bluish tinge, Presence of visible purple chromatin

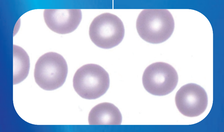

Erythrocyte (mature)
Size : 7-8 µm
Cytoplasm : The central area of pallor occupies between 1/3 and 2/3 of the diameter

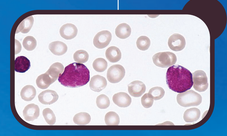

Lymphoblast
Size : Small to medium, 7 to 15 µm
N/C* ratio : Very elevated
Nucleus : central, irregular, fine chromatin, rare nucleolus
Cytoplasm : basophil, no granules

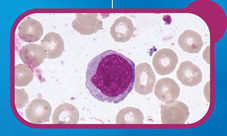

Prolymphocyte
Size : Medium, 12-15 µm
N/C ratio : Elevated, 0.9
Nucleus : central,dense chromatin with nucleolus
Cytoplasm : light basophil, no granules

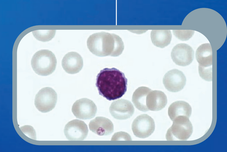

Small Lymphocyte
Size : 8-10 µm
N/C* ratio : 1
Nucleus : central, dense chromatin, no nucleolus
Cytoplasm : very light basophil

Large Lymphocyte
Size : 12-20 µm
N/C* ratio : medium
Nucleus : eccentric, dense chromatin, no nucleolus
Cytoplasm : very light basophil, hyalin

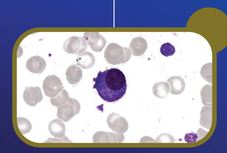

Plasma cell
Size : Small to medium, 10-15 µm
N/C* ratio : Medium
Nucleus : eccentric, round, coarse chromatin, no nucleolus
Cytoplasm : intense basophilia, Golgi apparatus adjacent to the nucleus (archoplasm)

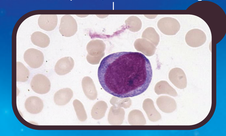

Monoblast
Size : 20-30 µm
N/C* ratio : medium/elevated
Nucleus : +/- round, fine chromatin, nucleolus
Cytoplasm : slightly basophilic, abundant cytoplasmic veils, azurophil grain dust

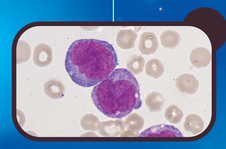

Promonocyte
Size : 20 µm
N/C* ratio : Medium, 0.4
Nucleus : central, no nucleolus, fine chromatin,
Cytoplasm : quite basophil, sometimes vacuolated

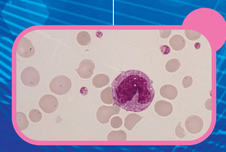

Monocyte
Size : 15-20 µm
N/C* ratio : Low, = 0.3
Nucleus : very irregular horseshoe- shaped, coarse chromatin
Cytoplasm : quite basophil (gray stormy sky cytoplasm), sometimes vacuolated, azurophils granules

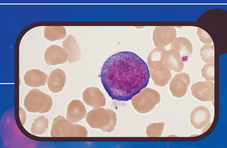

Myeloblast
Size : 15-20 µm
N/C* ratio : elevated, 0,7
Nucleus : eccentric, fine chromatin, nucleolus
Cytoplasm : basophilia, numerous azurophils granules

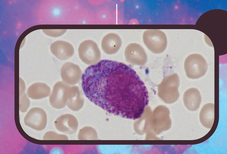

Promyelocyte
Size : 20 µm
N/C* ratio : medium, 0,5
Nucleus : eccentric, fine chromatin, nucleolus
Cytoplasm : basophilia, rares azurophils granules

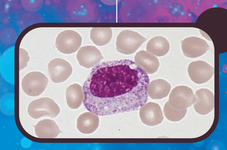

Myelocyte
Size : around 20 µm
N/C* ratio : medium, 0,5
Nucleus : eccentric, coarse chromatin, no nucleolus
Cytoplasm : no basophilia, numerous azurophils granules

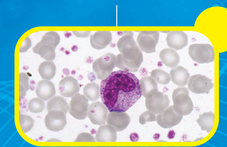

Metamyelocyte
Size : 15-20 µm
N/C* ratio : low,, 0,3
Nucleus : concave, coarse chromatin, no nucleolus
Cytoplasm : no basophilia, numerous neutrophilic granules (brown)

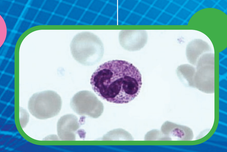

Segmented Neutrophil
Size : 12-15 µm
N/C* ratio : medium, 0,4
Nucleus : dense chromatin, segmented (2-5 lobes)
Cytoplasm : unstained, fine neutropilic granules

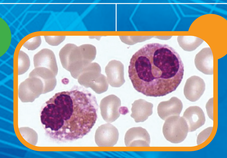

Eosinophil
Size : 12-15 µm
N/C* ratio : medium, 0,4
Nucleus : dense chromatin,bilobed
Cytoplasm : unstained, large eosinophilic granules

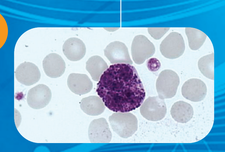

Basophil
Size : 12-15 µm
N/C* ratio : medium, 0,4
Nucleus : dense chromatin,bilobed
Cytoplasm : unstained, large basophilic granules

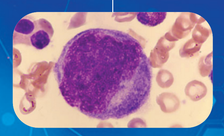

Megakaryoblast
Size : 20-30 µm
N/C* ratio : elevated
Nucleus : round or bilobed, fine chromatine
Cytoplasm : very basophil without granules

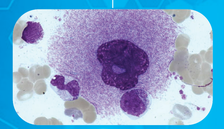

Megakaryocyte
Size : 40-100 µm
Nucleus : polylobed, varuiable shape, Dense chromatin
Cytoplasm : abundant, acidophil, numerous granules

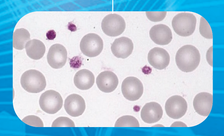

Platelets
Size : 2-5 µm
Nucleus : no nucleus
Cytoplasm : purple, violet particles

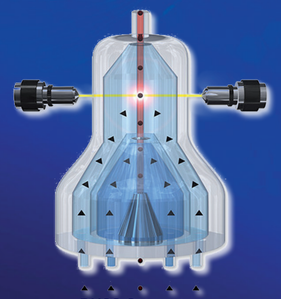

DHSS Cytometer

Available on Yumizen H series

10 DIF => 10 nucleated subpopulations routinely differenciated :
Lymphocyte, Monocyte, Neutrophil, Eosinophil, Basophil, Atypical Lymphocyte, Erythroblast, Immature Granulocyte, Immature Monocyte, Immature Lymphocyte

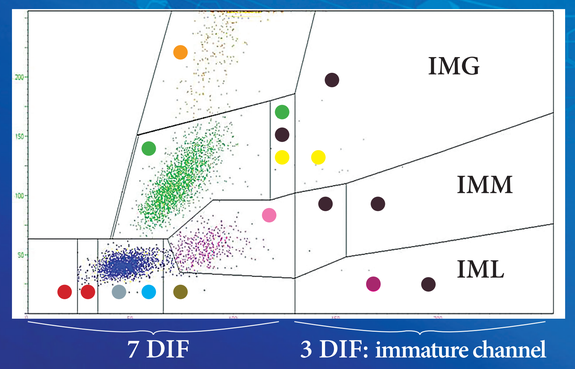

www.horiba.com/medical

*Nucleus/Cytoplasm ratio